

## REVIEW ARTICLE

Julie R. Ingelfinger, M.D., *Editor*

## Point-of-Care Ultrasonography

José L. Díaz-Gómez, M.D., Paul H. Mayo, M.D., and Seth J. Koenig, M.D.

**P**OINT-OF-CARE ULTRASONOGRAPHY (POCUS) IS DEFINED AS THE ACQUISITION, interpretation, and immediate clinical integration of ultrasonographic imaging performed by a treating clinician at the patient's bedside rather than by a radiologist or cardiologist. POCUS is an inclusive term; it is not limited to any specialty, protocol, or organ system.<sup>1</sup> With the advent of smaller and more affordable ultrasound machines, combined with evidence that nonradiologists and noncardiologists can become competent in the performance of POCUS, it is now used in many practice settings and in all phases of care — from screening and diagnosis to procedural guidance and monitoring — and has become associated with changes in clinical decision making in medical practice.<sup>2,3</sup> A recent study showed that POCUS facilitated confirmation of the suspected clinical diagnosis in up to 50% of cases and supported a change in the initial diagnosis in 23% of cases.<sup>4</sup> In this review, we discuss key trends in POCUS technology, advances in its clinical applications, and the overlap and complementarity of POCUS and consultative ultrasonography in primary imaging specialties, as shown in Figure 1.

From the Baylor College of Medicine, Houston (J.L.D.-G.); and the Donald and Barbara Zucker School of Medicine at Hofstra/Northwell, Hempstead (P.H.M.), and the Albert Einstein College of Medicine, New York (S.J.K.) — both in New York. Address reprint requests to Dr. Díaz-Gómez at the Division of Cardiovascular Anesthesiology and Critical Care Medicine, Baylor College of Medicine, 6720 Bertner Ave., Suite O-520, Houston, TX 77030, or at jose.diaz-gomez@bcm.edu.

N Engl J Med 2021;385:1593-602.

DOI: 10.1056/NEJMra1916062

Copyright © 2021 Massachusetts Medical Society.

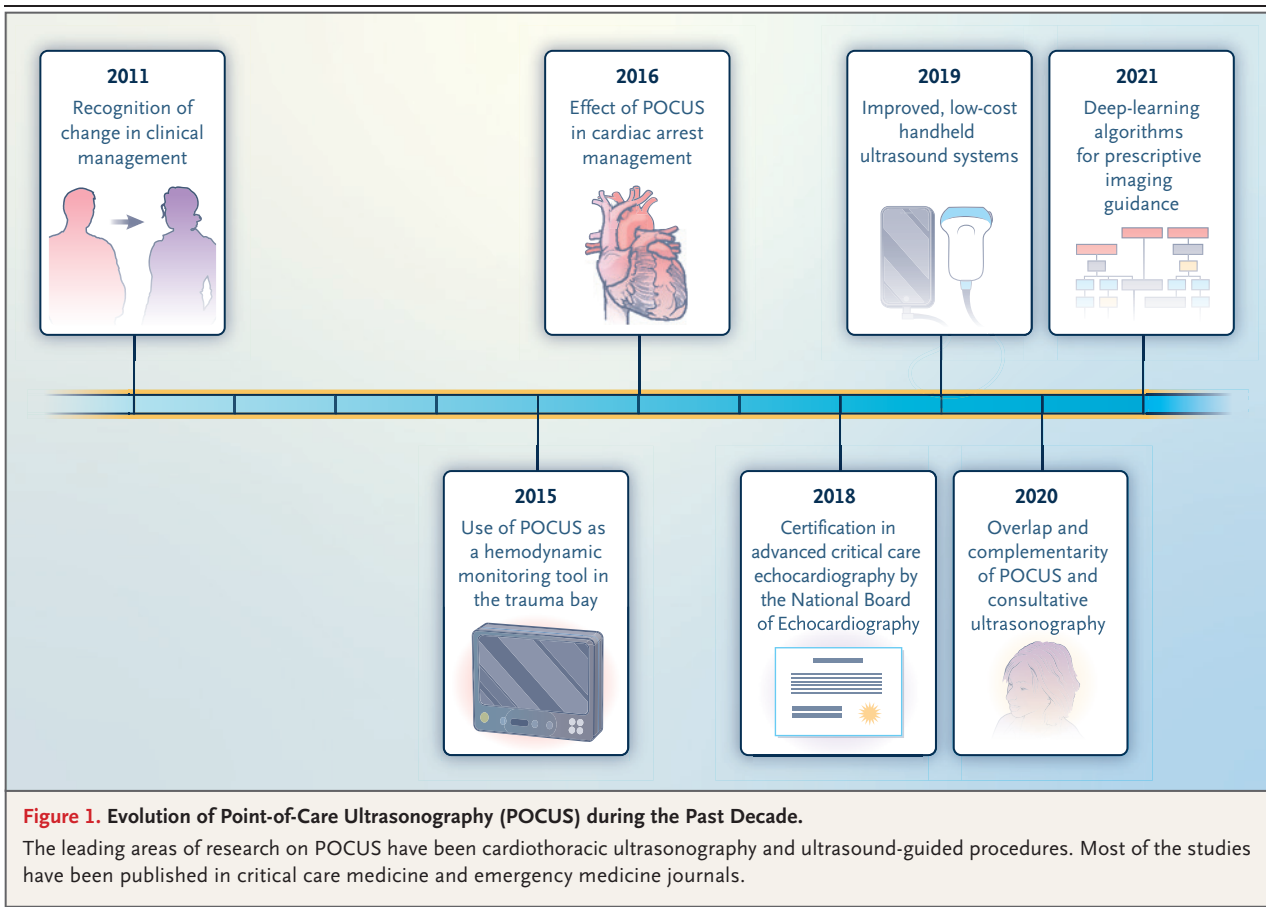
**CME**  
at NEJM.org

## POCUS AND CONSULTATIVE ULTRASONOGRAPHY

As a point-of-care imaging technique, POCUS requires direct interaction between the clinician and the patient to establish a clinical diagnosis or guide a procedure. Thus, it differs from consultative ultrasonography, in which the test is ordered by the clinician, typically performed by a technician, and then interpreted by a consultant who is not directly involved with the care of the patient.<sup>5</sup> Since POCUS challenges the traditional approach to ultrasonography and involves the clinician directly, it may well result in a reduction in the use of consultative ultrasonographic services.<sup>6-8</sup>

A 2015 retrospective study showed that the introduction of point-of-care echocardiography performed by intensivists led to a decreased number of comprehensive diagnostic echocardiographic studies overall but led to a recommendation to perform full diagnostic echocardiographic studies in 10.7% of patients who had undergone the point-of-care studies.<sup>9</sup> This change in practice occurred without adverse clinical outcomes.<sup>9</sup> However, such practice changes may engender concern in the radiology and cardiology communities about reduced reimbursement and potential quality issues. Professional societies such as the American Society of Echocardiography<sup>10</sup> have provided guidance on the use of POCUS, and there is evidence that consultative diagnostic and therapeutic ultrasonography can be complementary to POCUS.<sup>6,10</sup>

The American Society of Echocardiography, in concert with multiple specialties that use POCUS in clinical practice, recommends that, to ensure high-quality care, both cardiologists and sonographers facilitate the education and direct training of clinicians who perform cardiac ultrasonography.<sup>10</sup> North American radiology



societies have delineated what they consider the proper scope and use of POCUS and have advocated the adoption of a framework that defines POCUS as a tool that enhances evaluation and management. These professional societies emphasize the finite nature of POCUS and recommend its use by well-trained operators.<sup>2,11</sup>

#### KEY TRENDS IN POCUS TECHNOLOGY

##### HANDHELD ULTRASOUND SYSTEMS

Low-cost handheld ultrasound systems that connect to a smartphone or tablet by means of sophisticated wireless technology, the Internet, and a cloud-based system have become readily available to the frontline clinician. Thus, video conferencing and peer imaging evaluation (in which an experienced peer can evaluate POCUS imaging remotely on a real-time basis) for clinical, training, or mentoring purposes are now feasible.<sup>12</sup>

The number of probes necessary for studies

affects cost. One handheld ultrasound system uses silicon-chip array microsensors instead of piezoelectric crystal elements, which means that a single probe can be used for both vascular and body imaging.<sup>13,14</sup> Another design features a double-ended probe with traditional piezoelectric crystals, so the probe can be used for both vascular and body imaging. Combining vascular and body imaging capability in one probe reduces acquisition costs related to the device.

Several handheld ultrasound systems can perform linear measurements and have full-spectrum Doppler, M-mode, analytics, and quantitation features to facilitate POCUS applications in multiple subspecialty settings.<sup>13,15</sup> In 2020, the Food and Drug Administration cleared for use a handheld ultrasound system that has full-spectrum Doppler capability, which had not previously been available in any handheld system. This capability allows for a variety of quantitative measurements. Clinicians who use handheld

systems that have these new algorithms for quantitation can obtain an automated measurement of the left ventricular ejection fraction, estimate the volume of pleural effusions or urinary bladder volume, and detect valvular heart disease. Handheld POCUS systems are useful in telemedicine and triage and directly affect length of stay.<sup>16,17</sup>

Careless use of handheld ultrasound systems could lead to violations of the Health Insurance Portability and Accountability Act (HIPAA) in the United States (or similar regulations in other countries). Clinicians who use these systems should anticipate concern on the part of their information technology colleagues about Internet connectivity and the need for technical solutions to prevent HIPAA violations.

#### ARTIFICIAL INTELLIGENCE AND POCUS

Deep-learning approaches are revolutionizing decision making in medical imaging. Ultrasonography provides ideal data for these transformative approaches because of its widespread availability, even in low-resource environments and prehospital settings.<sup>18</sup> Despite technological advances in machine design, there is still limited artificial intelligence that is based on quantitative analysis. Implementation of fully automated machine-learning algorithms — for example, for left and right ventricular systolic function, presence of pericardial effusion, prediction of fluid responsiveness or severity of acute lung disease, detection of free abdominal fluid, and prescriptive imaging guidance — is an active area of development and research.<sup>19-21</sup>

Classification of benchmark ultrasound images is a requirement for training a convolutional neural network (a type of artificial neural network based on the pattern of connectivity of neurons in the human brain and used in deep learning); a new convolutional neural network has already been trained to classify multiorgan POCUS examinations, with promising results.<sup>22</sup> In combination with clinician expertise, clinically relevant decision making may become more effective with this deep-learning trajectory. In the case of prescriptive POCUS guidance, one study showed that novice operators were able to obtain a 10-view echocardiographic image set that was similar in quality to that obtained by skilled cardiac sonographers.<sup>19</sup> Automated ultra-

sonographic training with immediate and direct feedback to learners has been shown to shorten the learning curve, a potential step in the development of new training models for POCUS and increased interoperator reproducibility of results.<sup>3,18</sup>

#### CLINICAL DOCUMENTATION

Contemporary POCUS machines store images in the digital imaging and communications in medicine (DICOM) format, which allows them to be uploaded to a picture archiving and communication system or to commercially available, stand-alone digital storage systems. Such storage of images facilitates quality assurance processes, standardized documentation, and billing.<sup>23</sup> Graphic communication, a recent advance in telemedicine and clinical documentation,<sup>24</sup> allows providers in different locations to engage in continuous quality assurance, education, and clinical decision making while using the same server.

#### USE OF POCUS FOR GUIDANCE IN PERFORMING PROCEDURES

Imaging-guided diagnostic and therapeutic procedures are a mainstay of contemporary clinical practice to reduce morbidity and to improve safety, operator effectiveness, and immediate symptom relief after thoracentesis,<sup>3,25</sup> paracentesis,<sup>26</sup> lumbar puncture,<sup>27</sup> central venous access,<sup>28</sup> peripheral venous and arterial access,<sup>29,30</sup> pericardiocentesis,<sup>31</sup> abscess drainage,<sup>32</sup> and joint aspiration.<sup>33</sup> The availability of portable machines permits POCUS to be used for procedural guidance on site by office-based clinicians, hospitalists, emergency medicine clinicians, and intensivists.

Use of ultrasonography to guide procedures requires that the clinician be competent in its use for specialty-specific functions. Clinicians can develop technical competence with task trainers (simulators that integrate ultrasonography with the physical aspects of a specific procedure and allow repeated practice before an encounter with a patient). On the basis of expert consensus, 25 to 50 examinations are required to ensure basic competence in performing most diagnostic ultrasonographic procedures. The acquisition of competence in ultrasonography for guidance during procedures appears to have a shorter learning curve (10 procedures).<sup>34-36</sup> However, a numerical standard alone cannot be used

to determine competence in POCUS-driven procedures, given the level of the data. At present, there is no widely accepted method of determining competence in the performance of ultrasonography to guide procedures.

#### POCUS EXAMINATIONS FOR CLINICAL MONITORING

Clinicians who become proficient in POCUS can use it to track clinical conditions that may progress rapidly — for example, acute respiratory failure, intracranial hypertension, and hemodynamic failure and resuscitation from traumatic shock.<sup>37-39</sup> A prospective, randomized, controlled study of the value of limited transthoracic echocardiography as a monitoring tool in patients with severe injuries and hypotension who were seen in the trauma section of an emergency department showed that the use of this form of POCUS reduced mortality and the time to operative intervention.<sup>40</sup> Monitoring applications that use POCUS require repeat examinations and use semiquantitation or quantitation when indicated.<sup>38</sup> For instance, a POCUS assessment of patients with decompensated heart failure or coronavirus disease 2019 (Covid-19) can facilitate clinical decision making during triage, evaluation of implemented therapeutic interventions, and tracking of disease activity (see Video S1 in the Supplementary Appendix, available with the full text of this article at NEJM.org).<sup>39</sup>

POCUS can be useful as a monitoring tool during the performance of cardiopulmonary resuscitation (CPR). To use this approach during CPR, a POCUS operator is tasked with assessing cardiac function serially, during the brief periodic interruptions of chest compressions that are part of the standard CPR sequence. This application of POCUS requires the operator to be competent in rapid image acquisition in the 10-second period that is conventionally used to perform a pulse check (i.e., seek a palpable pulse) during CPR.<sup>41,42</sup> Serial POCUS images during these 10-second pulse checks facilitate the recognition of pseudo-pulseless electrical activity, which is defined as organized cardiac activity identified by echocardiography in the absence of a detectable pulse. In contrast, pulseless electrical activity is characterized by a lack of cardiac activity on echocardiography. Pseudo-pulseless electrical activity may

be associated with potentially treatable conditions.<sup>43,44</sup> Current CPR guidelines recommend that the duration of pulse checks be limited to 10 seconds, since minimizing interruptions is associated with improved rates of return of spontaneous circulation and survival to hospital discharge. This arouses concern that using POCUS for characterization of cardiac arrest might prolong the time to the pulse check. One study showed that this was the case.<sup>41</sup> However, this finding was contradicted in a subsequent study, which showed that the use of POCUS during the pulse check reduced the duration of pulse checks.<sup>41,42</sup> Another benefit of using POCUS during CPR is the reliable detection of a carotid pulse.<sup>45</sup>

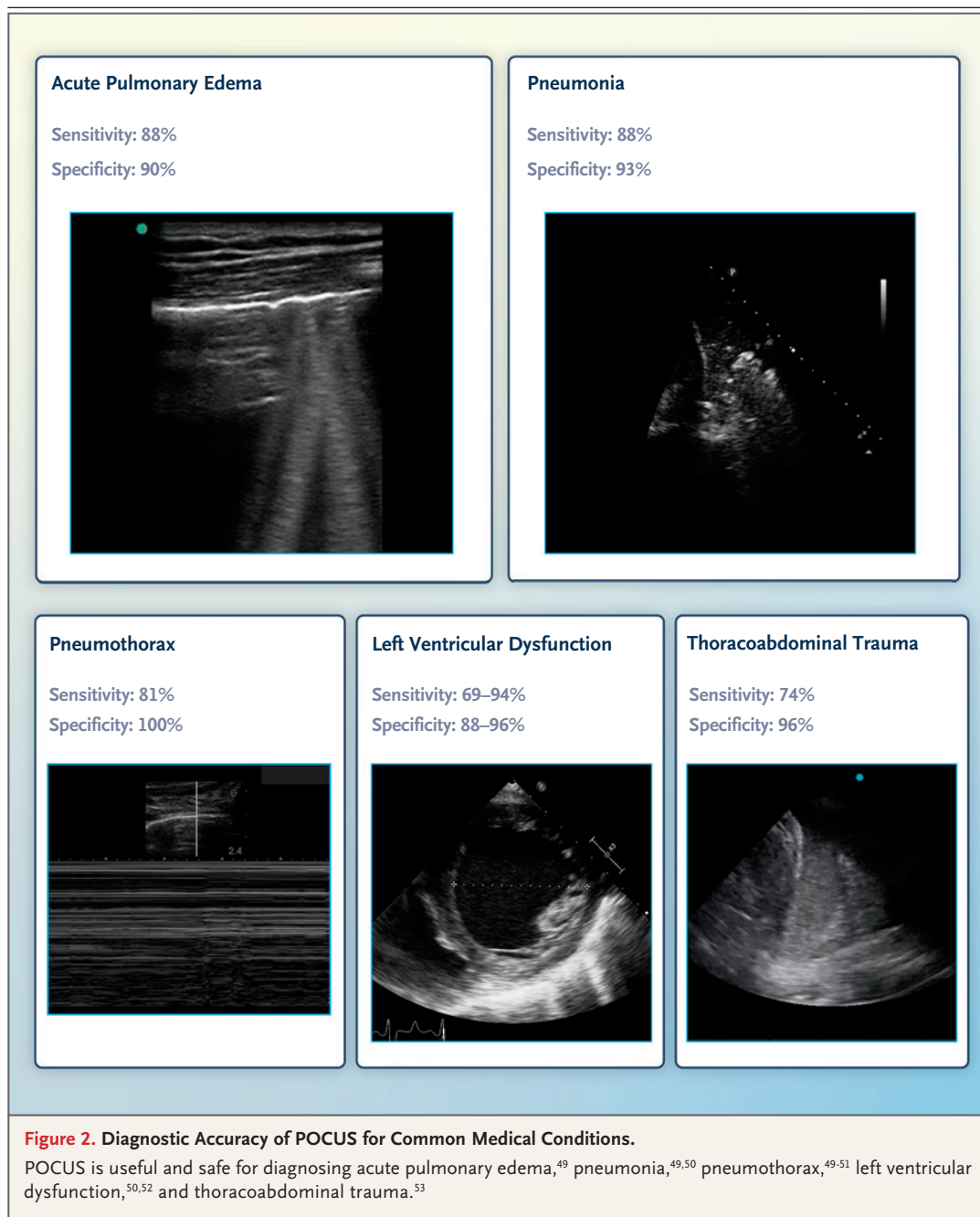
A multicenter, prospective, protocol-driven observational study involving 793 cases of out-of-hospital or emergency-department cardiac arrest documented organized cardiac activity on POCUS in some cases, which was associated with an increased likelihood of survival from the initial resuscitation to hospital discharge.<sup>46</sup> An absence of cardiac activity on POCUS was associated with a very low rate of survival. POCUS was useful in identifying pericardial effusion that responded to pericardiocentesis.<sup>46</sup> POCUS may also provide clinical guidance in deciding whether to cease or continue CPR when the capnographic values are very low or gas is present in the hepatic vein.<sup>47,48</sup>

#### ADVANCES IN THE CLINICAL APPLICATION OF POCUS

##### DIAGNOSTIC ACCURACY

How POCUS compares with other imaging techniques in general use, apart from its low cost, time efficiency, and ease of use, is a key question. The accuracy of POCUS supports its benefit in the evaluation of common medical conditions (Fig. 2).<sup>49-54</sup> POCUS is effective as a screening tool for the identification of certain disorders, such as abdominal aortic aneurysm.<sup>49</sup>

A relevant example of the diagnostic accuracy of POCUS is its value in characterizing non-specific clinical conditions, including respiratory distress and chest pain, as compared with chest radiography. In a prospective study involving 2683 patients evaluated for dyspnea in the emergency department, there were no significant



differences in accuracy between POCUS and standard evaluation that included chest radiography for the diagnosis of an acute coronary syndrome, pneumonia, pleural effusion, pericardial effusion, pneumothorax, or dyspnea from other causes.<sup>50</sup> POCUS was more sensitive for the diagnosis of heart failure, but standard evaluation performed better in the diagnosis of chron-

ic obstructive pulmonary disease and pulmonary embolism.<sup>50</sup> In another prospective study, involving 128 patients presenting to the emergency department with dyspnea and chest pain, a chest radiograph did not add actionable clinical information for patients with a normal thoracic POCUS study.<sup>55</sup>

Using an expedited, modified Delphi consen-



sus approach, an international, multispecialty expert panel evaluated clinically integrated, multi-organ POCUS for management of Covid-19. The results led the panel to suggest that POCUS was useful in nine clinical domains (diagnosis of severe acute respiratory syndrome coronavirus 2 [SARS-CoV-2] infection, initial triage and risk stratification, diagnosis of Covid-19 pneumonia, diagnosis of cardiovascular disease, screening for venous thromboembolic disease, respiratory support strategies, management of fluid therapy, clinical monitoring of patients with Covid-19, and infection control to reduce the environmental spread of infection and risk of infection for health care providers).<sup>39</sup>

#### EFFICIENCY AND COST-EFFECTIVENESS

Several studies indicate that POCUS is more cost-effective and time-efficient than traditional ultrasonography in obtaining data that may decrease the length of stay in the emergency department (for evaluation of nephrolithiasis, uncomplicated biliary disease, early intrauterine pregnancy, and soft-tissue infection).<sup>56-59</sup> Implementation of POCUS for a broad range of clinical conditions in general medical practice has led to a measurable reduction in planned referrals.<sup>60</sup> Similar findings have been reported by cardiologists and trainees who use POCUS in the triage of patients with suspected cardiac disease.<sup>16</sup>

For peritonsillar abscess, the use of POCUS in evaluation and management resulted in more efficacious aspiration and decreased subspecialist consultation, less computed tomographic imaging, fewer return visits, and a shorter length of stay, as compared with the conventional clinical approach.<sup>61</sup> POCUS can be efficiently used in patients receiving palliative care to address symptoms such as severe dyspnea due to malignant pleural effusions and has benefits with regard to triage, patient satisfaction, and cost-effectiveness.<sup>26,62</sup>

#### MORBIDITY AND MORTALITY

Evidence that the use of POCUS reduces morbidity and mortality remains elusive. The first randomized clinical trial evaluating the effect of early POCUS on hospital discharge and 30-day mortality showed little benefit (with respect to survival, length of stay, fluid administration, and use of inotropes) when POCUS was used to

assess patients with hypotension, as compared with conventional clinical management without POCUS.<sup>63</sup> However, the study suggested that POCUS can improve diagnostic accuracy and characterization of arterial hypotension in the emergency department. Methodologic limitations of the study included the use of a limited POCUS examination, early termination of patient enrollment, and lack of information about whether the use of POCUS to establish diagnoses resulted in appropriate management decisions. However, a systematic review partially supported the use of POCUS to guide fluid resuscitation in surgical patients and septic non-surgical patients with shock, reducing adverse effects, organ failure, and mortality.<sup>64</sup>

#### COMPETENCE AND TRAINING IN POCUS

It is self-evident that the clinician who uses POCUS must be competent in its use. Clinicians who have not been adequately trained may harm patients by making an inaccurate diagnosis or using POCUS inappropriately. In 2020, the Joint Commission on Accreditation of Healthcare Organizations and the Emergency Care Research Institute identified the adoption of POCUS without necessary safeguards as a major health technology hazard.<sup>65</sup>

With the widespread availability of lower-cost handheld ultrasound systems, training large numbers of clinicians to become competent in POCUS poses a challenge. The development of training curricula and methods to assess competence is imperative for the safe and effective use of such systems.<sup>66</sup> At the medical school level, 35% of 222 medical schools in the United States have implemented a focused ultrasound training program.<sup>66-68</sup> In one study, integrating POCUS into the abdominal physical examination improved the ability of medical students to accurately identify abnormalities.<sup>69</sup> Also, after POCUS training, medical students found new diagnoses and decreased triage time with a high concordance with attending physicians.<sup>70</sup> On the basis of collaborative research, the American Society of Echocardiography and the Canadian Society of Echocardiography have created a cardiovascular POCUS curriculum for medical students.<sup>71,72</sup> It is not known how widely this curriculum has been adopted.

**Table 1. Comparison of Point-of-Care Ultrasonography (POCUS) and Consultative Ultrasonography.\***

Point of Comparison	POCUS Performed by Nonradiologists and Noncardiologists	Consultative Ultrasonography Performed by Radiologists and Cardiologists
Scope of practice and ultrasonographic workflow	POCUS, combined with history taking and physical examination, performed for specific clinical conditions by the clinician directly responsible for medical management	Clinician directly responsible for medical management orders ultrasonographic evaluation, performed by sonographer and interpreted by radiologist or cardiologist
Examples of training requirements for competency	ACGME core competency for general surgery residency, anesthesiology residency, critical care fellowship† ACEP clinical ultrasound accreditation: emergency medicine residency training pathway — residency program director assesses competence of board-eligible or certified physician in specific components of ultrasonography — or practice pathway involving >16 hr of didactics and >25 high-quality examinations for each application or >150 total ultrasound procedures in a wide variety of applications EDEC requirements for advanced critical care echocardiography: 100 TTE and 30 TEE procedures performed and interpreted, written examination designed by ESICM NBE certification in critical care echocardiography: written examination designed by NBME, 150 TTE examinations performed and interpreted ASUM requirements: 300 TTE and 50 TEE procedures performed and interpreted, 50 vascular or lung ultrasound procedures, no written examination	ACGME core competency for radiology residency: ≥350 abdominal or pelvic ultrasound examinations, ≥25 image-guided drainage procedures ACGME core competency for cardiology fellowship: 3 mo of dedicated echocardiographic training NBE certification for independent performance of advanced perioperative TEE after completion of cardiac anesthesia fellowship or practice pathway for applicants who finished core residency before July 1, 2009: 150 TEE procedures performed, 300 interpreted NBE certification for independent performance and interpretation of echocardiography after completion of adult cardiovascular disease fellowship or practice pathway with specific board requirements: level II competence — 150 TTE procedures performed and 300 interpreted, 50 TEE procedures performed and interpreted; level III competence — 150 TTE procedures performed and 750 interpreted, 150 TEE procedures performed and interpreted
Possible limitations	Inadequate training and lack of competence, with potential for false positive and false negative examinations Heterogeneous documentation of training, quality assurance, and credentialing standards across hospital and clinic medical practices	Delay in performance, interpretation, and communication of results to physician directly responsible for management, compounded by consultant's lack of full knowledge of clinical situation Increased health care costs and lack of immediate availability of consultative services

\* ACEP denotes American College of Emergency Physicians, ACGME Accreditation Council for Graduate Medical Education, ASUM Australasian Society for Ultrasound in Medicine, EDEC European Diploma in Advanced Critical Care Echocardiography, ESICM European Society of Intensive Care Medicine, NBE National Board of Echocardiography, NBME National Board of Medical Examiners, TEE transesophageal echocardiography, and TTE transthoracic echocardiography.

† Training is required but without the requirement of a dedicated training period.

Specialty-specific training in POCUS and methods that test for competence are important for postgraduate medical training. The Accreditation Council for Graduate Medical Education defines requirements for ultrasonographic training in emergency medicine and anesthesiology residencies. An innovative approach to fellowship-level training has been the development of regional, multiday cooperative courses that provide a standard initial training sequence followed by on-site training during critical care fellowships.<sup>73</sup> In the United States and Canada, training standards have been formulated for specialty-specific POCUS, but national-level postgraduate certification is generally not available for the many applications of POCUS. The United Kingdom and Australia and New Zealand have well-designed national standards for certification in specialty-

specific POCUS. In the United States and Canada, the National Board of Echocardiography offers national certification in advanced critical care echocardiography (Table 1),<sup>66,74,75</sup> and the European Society of Intensive Care Medicine offers a similar certification. Both certifications are open to international physicians. Advanced critical care echocardiography, a recent addition to POCUS in critical care, comprises all relevant components of echocardiography, with additional elements specific to critical care.

#### UNANSWERED QUESTIONS ABOUT POCUS

Two questions about POCUS remain unanswered. First, does POCUS affect patient-centered end points such as functional status, morbidity, and

mortality? The effect of POCUS on patient outcomes is a challenge to study, given the heterogeneity of the patient populations, the lack of standardized therapeutic plans based on POCUS results, the difficulty in standardizing scanning protocols, the confounding effect of concurrent therapeutic interventions, variation in skill levels on the part of the clinicians performing POCUS, and the difficulty in finding clinicians with clinical equipoise regarding POCUS. It is not likely that focusing on POCUS as the primary variable determining the outcome will be a productive approach to research.

Second, what specific training is required for a clinician to become competent in POCUS? The field needs information to identify the hours of training required to achieve mastery of image acquisition, image interpretation, and the cognitive base; the course design; the usefulness of simulators and training programs embedded in the ultrasonography machine; the design of summative examinations of skill; and the ongoing assessment of maintenance of skill. A key aspect

to the success of a training sequence for POCUS also relates to the skill and motivation of the faculty, particularly with regard to hands-on training. This is an unexamined area of research.

## CONCLUSIONS

The use of POCUS is not limited to one specialty, protocol, or organ system. POCUS provides the treating clinician with real-time diagnostic and monitoring information and can be used to enhance the safety of standard ultrasound-guided procedures. The introduction of POCUS curricula and training at the medical school and postgraduate levels, the increasing level of evidence of its effect in clinical practice, and advances in handheld systems all point toward the possibility that POCUS will become a standard tool of the frontline clinician. However, it will be critical to determine which, if any, applications ultimately benefit patient care.

Disclosure forms provided by the authors are available with the full text of this article at NEJM.org.

## REFERENCES

- Moore CL, Copel JA. Point-of-care ultrasonography. *N Engl J Med* 2011;364:749-57.
- Patel MD, Horrow MM, Kamaya A, et al. Mapping the ultrasound landscape to define point-of-care ultrasound and diagnostic ultrasound: a proposal from the Society of Radiologists in Ultrasound and ACR Commission on Ultrasound. *J Am Coll Radiol* 2021;18:42-52.
- Riishede M, Laursen CB, Teglbjærg LS, et al. Diagnostic value of whole-body-focused ultrasonography in high-acuity patients in the emergency department: a prospective single-center cross-sectional study. *Ultrasound J* 2019;11:11.
- Baker DE, Nolting L, Brown HA. Impact of point-of-care ultrasound on the diagnosis and treatment of patients in rural Uganda. *Trop Doct* 2021;51:291-6.
- Marbach JA, Almuflleh A, Di Santo P, et al. A shifting paradigm: the role of focused cardiac ultrasound in bedside patient assessment. *Chest* 2020;158:2107-18.
- Kaplan SL, Chen AE, Rempell RG, Brown N, Velez-Florez MC, Khwaja A. Impact of emergency medicine point-of-care ultrasound on radiology ultrasound volumes in a single pediatric emergency department. *J Am Coll Radiol* 2020;17:1555-62.
- Pontet J, Yic C, Díaz-Gómez JL, et al. Impact of an ultrasound-driven diagnostic protocol at early intensive-care stay: a randomized-controlled trial. *Ultrasound J* 2019;11:24.
- Oks M, Cleven KL, Cardenas-Garcia J, et al. The effect of point-of-care ultrasonography on imaging studies in the medical ICU: a comparative study. *Chest* 2014;146:1574-7.
- Alherbish A, Priestap F, Arntfield R. The introduction of basic critical care echocardiography reduces the use of diagnostic echocardiography in the intensive care unit. *J Crit Care* 2015;30(6):1419.e7-1419.e11.
- Kirkpatrick JN, Grimm R, Johri AM, et al. Recommendations for echocardiography laboratories participating in cardiac point of care cardiac ultrasound (POCUS) and critical care echocardiography training: report from the American Society of Echocardiography. *J Am Soc Echocardiogr* 2020;33(4):409-422.e4.
- Chawla TP, Cresswell M, Dhillon S, et al. Canadian Association of Radiologists position statement on point-of-care ultrasound. *Can Assoc Radiol J* 2019;70:219-25.
- Salerno A, Tupchong K, Verceles AC, McCurdy MT. Point-of-care teleultrasound: a systematic review. *Telemed J E Health* 2020;26:1314-21.
- Baribeau Y, Sharkey A, Chaudhary O, et al. Handheld point-of-care ultrasound probes: the new generation of POCUS. *J Cardiothorac Vasc Anesth* 2020;34:3139-45.
- Lee L, DeCara JM. Point-of-care ultrasound. *Curr Cardiol Rep* 2020;22:149.
- Austin DR, Chang MG, Bittner EA. Use of handheld point-of-care ultrasound in emergency airway management. *Chest* 2021;159:1155-65.
- Kobal SL, Liel-Cohen N, Shimony S, et al. Impact of point-of-care ultrasound examination on triage of patients with suspected cardiac disease. *Am J Cardiol* 2016;118:1583-7.
- Galusko V, Bodger O, Ionescu A. A systematic review of pocket-sized imaging devices: small and mighty? *Echo Res Pract* 2018;5:113-38.
- Shokoohi H, LeSaux MA, Roohani YH, Liteplo A, Huang C, Blaivas M. Enhanced point-of-care ultrasound applications by integrating automated feature-learning systems using deep learning. *J Ultrasound Med* 2019;38:1887-97.
- Narang A, Bae R, Hong H, et al. Utility of a deep-learning algorithm to guide novices to acquire echocardiograms for limited diagnostic use. *JAMA Cardiol* 2021;6:624-32.
- Roy S, Menapace W, Oei S, et al. Deep learning for classification and localization of COVID-19 markers in point-of-care lung ultrasound. *IEEE Trans Med Imaging* 2020;39:2676-87.
- Sjogren AR, Leo MM, Feldman J, Gwin



- JT. Image segmentation and machine learning for detection of abdominal free fluid in focused assessment with sonography for trauma examinations: a pilot study. *J Ultrasound Med* 2016;35:2501-9.
22. Blaivas M, Arntfield R, White M. DIY AI, deep learning network development for automated image classification in a point-of-care ultrasound quality assurance program. *J Am Coll Emerg Physicians Open* 2020;1:124-31.
23. Flannigan MJ, Adhikari S. Point-of-care ultrasound work flow innovation: impact on documentation and billing. *J Ultrasound Med* 2017;36:2467-74.
24. Cohen GI. A practical guide to graphic communication for quality assurance, education, and patient care in echocardiography. *Echocardiography* 2019;36:1747-54.
25. Helgeson SA, Fritz AV, Tatari MM, Daniels CE, Diaz-Gomez JL. Reducing iatrogenic pneumothoraces: using real-time ultrasound guidance for pleural procedures. *Crit Care Med* 2019;47:903-9.
26. Wang J, Khan S, Wyer P, et al. The role of ultrasound-guided therapeutic paracentesis in an outpatient transitional care program: a case series. *Am J Hosp Palliat Care* 2018;35:1256-60.
27. Abraham A, Breiner A, Katzberg HD, Lovblom LE, Bril V. Ultrasound-assisted lumbar puncture in a neuromuscular clinic has a high success rate and less pain. *Can J Neurol Sci* 2019;46:79-82.
28. Smit JM, Raadsen R, Blans MJ, Petjak M, Van de Ven PM, Tuinman PR. Bedside ultrasound to detect central venous catheter misplacement and associated iatrogenic complications: a systematic review and meta-analysis. *Crit Care* 2018;22:65.
29. Bhattacharjee S, Maitra S, Baidya DK. Comparison between ultrasound guided technique and digital palpation technique for radial artery cannulation in adult patients: an updated meta-analysis of randomized controlled trials. *J Clin Anesth* 2018;47:54-9.
30. Franco-Sadud R, Schnobrich D, Mathews BK, et al. Recommendations on the use of ultrasound guidance for central and peripheral vascular access in adults: a position statement of the Society of Hospital Medicine. *J Hosp Med* 2019;14:E1-E22.
31. Maggolini S, Gentile G, Farina A, et al. Safety, efficacy, and complications of pericardiocentesis by real-time echo-monitored procedure. *Am J Cardiol* 2016;117:1369-74.
32. Gottlieb M, Avila J, Chottiner M, Peksas GD. Point-of-care ultrasonography for the diagnosis of skin and soft tissue abscesses: a systematic review and meta-analysis. *Ann Emerg Med* 2020;76:67-77.
33. Wu T, Dong Y, Song H, Fu Y, Li JH. Ultrasound-guided versus landmark in knee arthrocentesis: a systematic review. *Semin Arthritis Rheum* 2016;45:627-32.
34. Frankel HL, Kirkpatrick AW, Elbarbary M, et al. Guidelines for the appropriate use of bedside general and cardiac ultrasonography in the evaluation of critically ill patients. I. General ultrasonography. *Crit Care Med* 2015;43:2479-502.
35. Blehar DJ, Barton B, Gaspari RJ. Learning curves in emergency ultrasound education. *Acad Emerg Med* 2015;22:574-82.
36. Arbelot C, Dexheimer Neto FL, Gao Y, et al. Lung ultrasound in emergency and critically ill patients: number of supervised exams to reach basic competence. *Anesthesiology* 2020;132:899-907.
37. Yic CD, Prada G, Paz SI, et al. Comparison of ultrasonographic versus infrared pupillary assessment. *Ultrasound J* 2020;12:38.
38. Porter TR, Shillcutt SK, Adams MS, et al. Guidelines for the use of echocardiography as a monitor for therapeutic intervention in adults: a report from the American Society of Echocardiography. *J Am Soc Echocardiogr* 2015;28:40-56.
39. Hussain A, Via G, Melniker L, et al. Multi-organ point-of-care ultrasound for COVID-19 (PoCUS4COVID): international expert consensus. *Crit Care* 2020;24:702.
40. Ferrada P, Evans D, Wolfe L, et al. Findings of a randomized controlled trial using limited transthoracic echocardiogram (LTTE) as a hemodynamic monitoring tool in the trauma bay. *J Trauma Acute Care Surg* 2014;76:31-7.
41. Clattenburg EJ, Wroe PC, Gardner K, et al. Implementation of the Cardiac Arrest Sonographic Assessment (CASA) protocol for patients with cardiac arrest is associated with shorter CPR pulse checks. *Resuscitation* 2018;131:69-73.
42. Huis In 't Veld MA, Allison MG, Bostick DS, et al. Ultrasound use during cardiopulmonary resuscitation is associated with delays in chest compressions. *Resuscitation* 2017;119:95-8.
43. Rabjohns J, Quan T, Boniface K, Pourmand A. Pseudo-pulseless electrical activity in the emergency department, an evidence based approach. *Am J Emerg Med* 2020;38:371-5.
44. Zengin S, Yavuz E, Al B, et al. Benefits of cardiac sonography performed by a non-expert sonographer in patients with non-traumatic cardiopulmonary arrest. *Resuscitation* 2016;102:105-9.
45. Badra K, Coutin A, Simard R, Pinto R, Lee JS, Chenkin J. The POCUS pulse check: a randomized controlled crossover study comparing pulse detection by palpation versus by point-of-care ultrasound. *Resuscitation* 2019;139:17-23.
46. Gaspari R, Weekes A, Adhikari S, et al. Emergency department point-of-care ultrasound in out-of-hospital and in-ED cardiac arrest. *Resuscitation* 2016;109:33-9.
47. April MD, Long B. Does spontaneous cardiac motion, identified with point-of-care echocardiography during cardiac arrest, predict survival? *Ann Emerg Med* 2018;71:208-10.
48. Ramamurti P, Yamane D, Desai S, Boniface K, Drake A. Mortality in patients with hepatic gas on point-of-care ultrasound in cardiac arrest: does location matter? *J Clin Ultrasound* 2021;49:205-11.
49. Sorensen B, Hunskaar S. Point-of-care ultrasound in primary care: a systematic review of generalist performed point-of-care ultrasound in unselected populations. *Ultrasound J* 2019;11:31.
50. Zanobetti M, Scorpiniti M, Gigli C, et al. Point-of-care ultrasonography for evaluation of acute dyspnea in the ED. *Chest* 2017;151:1295-301.
51. Chan KK, Joo DA, McRae AD, et al. Chest ultrasonography versus supine chest radiography for diagnosis of pneumothorax in trauma patients in the emergency department. *Cochrane Database Syst Rev* 2020;7:CD013031.
52. Kimura BJ. Point-of-care cardiac ultrasound techniques in the physical examination: better at the bedside. *Heart* 2017;103:987-94.
53. Stengel D, Leisterer J, Ferrada P, Ekkernkamp A, Mutze S, Hoening A. Point-of-care ultrasonography for diagnosing thoracoabdominal injuries in patients with blunt trauma. *Cochrane Database Syst Rev* 2018;12:CD012669.
54. Javali RH, Loganathan A, Srinivasarangan M, et al. Reliability of emergency department diagnosis in identifying the etiology of nontraumatic undifferentiated hypotension. *Indian J Crit Care Med* 2020;24:313-20.
55. Buhumaid RE, St-Cyr Bourque J, Shookoobi H, Ma IWY, Longacre M, Litemple AS. Integrating point-of-care ultrasound in the ED evaluation of patients presenting with chest pain and shortness of breath. *Am J Emerg Med* 2019;37:298-303.
56. Hilsden R, Leeper R, Koichopolos J, et al. Point-of-care biliary ultrasound in the emergency department (BUSED): implications for surgical referral and emergency department wait times. *Trauma Surg Acute Care Open* 2018;3(1):e000164.
57. Lin MJ, Neuman M, Rempell R, Monuteaux M, Levy J. Point-of-care ultrasound is associated with decreased length of stay in children presenting to the emergency department with soft tissue infection. *J Emerg Med* 2018;54:96-101.
58. Panebianco NL, Shofer F, Fields JM, et al. The utility of transvaginal ultrasound in the ED evaluation of complications of first trimester pregnancy. *Am J Emerg Med* 2015;33:743-8.
59. Metzler IS, Smith-Bindman R, Moghaddasi M, Wang RC, Stoller ML, Chi T. Emergency department imaging modality effect on surgical management of nephrolithiasis: a multicenter, randomized clinical trial. *J Urol* 2017;197:710-4.
60. Andersen CA, Holden S, Vela J, Rath-

- leff MS, Jensen MB. Point-of-care ultrasound in general practice: a systematic review. *Ann Fam Med* 2019;17:61-9.
61. Gibbons RC, Costantino TG. Evidence-based medicine improves the emergent management of peritonsillar abscesses using point-of-care ultrasound. *J Emerg Med* 2020;59:693-8.
62. Breakey N, Osterwalder J, Mathis G, Lehmann B, Sauter TC. Point of care ultrasound for rapid assessment and treatment of palliative care patients in acute medical settings. *Eur J Intern Med* 2020; 81:7-14.
63. Atkinson PR, Milne J, Diegelmann L, et al. Does point-of-care ultrasonography improve clinical outcomes in emergency department patients with undifferentiated hypotension? An international randomized controlled trial from the SHoC-ED Investigators. *Ann Emerg Med* 2018;72: 478-89.
64. Plurad DS, Chiu W, Raja AS, et al. Monitoring modalities and assessment of fluid status: a practice management guideline from the Eastern Association for the Surgery of Trauma. *J Trauma Acute Care Surg* 2018;84:37-49.
65. Castro G. Top 10 health technology hazards for 2020. Oakbrook Terrace, IL: The Joint Commission, January 3, 2020 (<https://www.jointcommission.org/en/resources/news-and-multimedia/blogs/datetime-tjc/2020/01/top-10-health-technology-hazards-for-2020/>).
66. Díaz-Gómez JL, Frankel HL, Hernandez A. National certification in critical care echocardiography: its time has come. *Crit Care Med* 2017;45:1801-4.
67. Wong J, Montague S, Wallace P, et al. Barriers to learning and using point-of-care ultrasound: a survey of practicing internists in six North American institutions. *Ultrasound J* 2020;12:19.
68. Ultrasound in medical education portal. Laurel, MD: American Institute of Ultrasound in Medicine (<http://meded.aium.org/medical-schools>).
69. Wong CK, Hai J, Chan KYE, et al. Point-of-care ultrasound augments physical examination learning by undergraduate medical students. *Postgrad Med J* 2021;97:10-5.
70. Kumar A, Weng Y, Wang L, et al. Portable ultrasound device usage and learning outcomes among internal medicine trainees: a parallel-group randomized trial. *J Hosp Med* 2020;15(2):e1-e6.
71. Russ BA, Evans D, Morrad D, et al. Integrating point-of-care ultrasonography into the osteopathic medical school curriculum. *J Am Osteopath Assoc* 2017;117: 451-6.
72. Johri AM, Durbin J, Newbigging J, et al. Cardiac point-of-care ultrasound: state-of-the-art in medical school education. *J Am Soc Echocardiogr* 2018;31:749-60.
73. Patrawalla P, Narasimhan M, Eisen L, Shiloh AL, Koenig S, Mayo P. A regional, cost-effective, collaborative model for critical care fellows' ultrasonography education. *J Intensive Care Med* 2020;35: 1447-52.
74. Mayo PH, Koenig S. Advanced critical care echocardiography certification: an update. *Chest* 2020;158:48-9.
75. Panebianco NL, Mayo PH, Arntfield RT, et al. Assessing competence in critical care echocardiography: development and initial results of an examination and certification processes. *Crit Care Med* 2021; 49:1285-92.

Copyright © 2021 Massachusetts Medical Society.